Perspectives in Medicine (2012) 1, 104—107

Bartels E, Bartels S, Poppert H (Editors):
New Trends in Neurosonology and Cerebral Hemodynamics — an Update.
Perspectives in Medicine (2012) 1, 104—107

journal homepage: www.elsevier.com/locate/permed

Measuring the degree of internal carotid artery stenosis

Gerhard-Michael von Reutern*

Ambulantes Kardiologisches Zentrum, Neurologische Praxis, Kuechlerstrasse 2, 61231 Bad Nauheim, Germany

KEYWORDS
Carotid stenosis;
Degree of stenosis;
Doppler ultrasound;
Duplex sonography;
Peak systolic velocity

Summary The use of ultrasonic methods to evaluate carotid disease differs from country to country. Most popular is the criterion of flow velocity in the stenosis, a criterion influenced by multiple other factors than narrowing of the artery. On the other side angiography does not reliably measure area reduction, responsible for the hemodynamic effect of a stenosis. Therefore correlations of velocity and the degree of stenosis as measured by angiography were never satisfying. In a recent international consensus a multiparametric approach has been proposed aiming to reduce possible errors. This article illustrates some of the possible errors measuring flow velocity with Doppler ultrasound and discusses the background for using multiple criteria. Ultrasound can be used for clinical decision making. This is possible in a clear cut high degree stenosis and in low degree disease. The advantage of Doppler ultrasound is to describe best the hemodynamic consequences of vessel narrowing. This may yield important additional information in combination with other imaging modalities.
© 2012 Elsevier GmbH. Open access under CC BY-NC-ND license.

Introduction

In 1986, the first German guideline for measuring the degree of carotid stenosis with sonography based on an intersociety consensus was published [15]. At that time, continuous wave (CW) Doppler sonographic was the prevailing methodology. As part of duplex sonography B-Mode imaging was added as rather poor method for correcting the orientation of the Doppler beam and placement of the sample volume. CW Doppler criteria for estimating the degree of narrowing were mainly based on hemodynamic parameters. Later duplex criteria were established in accordance with the established CW Doppler sonographic criteria. The stenotic signal was categorised using descriptive terms and broad Doppler shift categories.

In North America, documentation through imaging is of special importance because of the division of duties between technician (examining) and physician (reading). Soon duplex sonography replaced C-Mode Doppler imaging and the simple ''Doppler ophthalmic test'' as one of the hemodynamic parameters became unpopular. Aiming to improve quantification of a stenosis the intrastenotic peak systolic velocity PSV (instead of Doppler frequencies) were recorded after correction for the angle of insonation. Several correlations between PSV and the degree of stenosis measured by X-ray angiography were published [10] and a consensus for threshold values based on a meta-analysis was published [4]. However all correlations between PSV and angiography showed a considerable scatter. Therefore the NASCET group [2] and recently the AHA did not recommend carotid surgery in symptomatic patients based on duplex sonography alone [8].

Abbreviations: ECST, the European Carotid Surgery Trial; NASCET, the North American Symptomatic Carotid Endarterectomy Trial.

* Tel.: +49 1715856099.
E-mail address: g.v.reutern@gmx.de

2211-968X © 2012 Elsevier GmbH. Open access under CC BY-NC-ND license.
doi:10.1016/j.permed.2012.02.040

Table 1 Set of main and secondary criteria. For further details see Ref. [10].

Main criteria
(1) B-Mode and color imaging
(2) Mean or threshold values of peak systolic velocities in the stenosis
(3) Poststenotic velocity
(4) Appearance of collateral flow (ophthalmic artery, circle of Willis)
Secondary criteria
(5) Prestenotic reduced flow in the CCA
(6) Poststenotic flow disturbances, severity and length
(7) End diastolic flow velocity in the stenosis
(8) Carotid ratio (ICA/CCA velocities)

In Germany, as in other European countries the local diameter narrowing (ESCT method) was popular whereas in the US the distal diameter of the internal carotid artery (ICA) was taken as denominator (distal diameter narrowing, NASCET method). The ESCT method results in higher degrees of stenosis especially in the range of up to 70% stenosis [11]. This opened the possibility of misuse by measuring following the ESCT method and recommending carotid surgery following the NASCET criterion of 70%. In consequence new intersociety guidelines were published in Germany [1] very similar to the first ones [15], but using the NASCET method as the morphologic correlate. In addition the role of color coded imaging for detecting low degree disease and total occlusion was added, as well as PSV values. Recently a similar consensus was reached by the Neurosonology Research Group (NSRG) of the WFN [10]. Both of these guidelines emphasize the difference between main or primary and additional criteria. They are listed in Table 1. This article shall outline the background of grading a stenosis and especially focus on the weighting of these ultrasonic criteria as main and secondary.

Two different methods to grade a stenosis

A stenosis can be graded following its morphologic or hemodynamic effect. The morphologic aspect is measured in mm or as percent diameter reduction. Additional features can be described as precise location or shape of the plaque, regular or irregular. The hemodynamic effect can be measured as local flow velocity at the level of a plaque or stenosis [13], pressure drop or reduced flow volume. Doppler ultrasound in its clinical application cannot measure the two last parameters directly, but make estimations by measuring prestenotic side to side differences, the appearance of collateral flow, the poststenotic pulsatility and velocity of flow and flow disturbances [6]. Both the morphologic parameters and the hemodynamic parameters can be translated to each other, i.e. ''a hemodynamic relevant stenosis corresponds to a $\geq$70% stenosis (NASCET)'', or ''in a 80% stenosis collateral flow via the circle of Willis is highly probable''. In general the final diagnosis will be expressed in % diameter reduction, as it is the tradition with angiography. In mild degrees of stenosis duplex sonography describes both the morphology and local hemodynamic as well. With increasing severity a precise morphologic description is more difficult due to calcium shadowing and reverberation. Hemodynamic parameters are however more useful. Angiography will have fewer problems to show the stenotic canal in a high degree stenosis, but the hemodynamic evaluation is less reliable or needs special techniques such as contralateral injection. In addition the more hemodynamically oriented ultrasonography and the more morphologically orientated angiography have both technical limitations, as it will be described in detail below. Therefore a perfect correlation between these different approaches is not possible. It has to be kept in mind, that the prognosis and therefore the rational for decisions are only indirectly linked with diameter reduction or pressure drop but with plaque instability, thrombus formation and embolisation. The final diagnosis in % stenosis is only a surrogate parameter for the risk of an imminent ischemic event whichever technique is used.

Limitations of angiography

X-ray angiography was the method chosen for the carotid surgery trials run in the second half of the 80s and published in the early 90s. They provided conclusive evidence for the benefit of surgery [9]. The problem of angiographic measurements is that the diameter is measured, but the hemodynamic effect of a stenosis is due to the degree of area reduction. This is one important reason for a good deal of the discrepancies between ultrasonic and angiographic measurements. The area of stenosis is seldom concentric, often semicircular or oval shaped. Especially a high degree stenosis may have a very irregular opening making it completely illusive to estimate area reduction by measuring the diameter. This irregular aspect can often only be realised by the surgeon during endarterectomy.

Limitations of ultrasonography

Spectral analysis

The most popular parameter is the peak systolic velocity (PSV) in the stenosis. The envelope of the Doppler spectrum is chosen instead of the instant mean Doppler shift and converted to velocity. The envelope of the spectrum is more reproducible than the instant mean especially in systole. The highest frequencies in systole are recorded from those streamlines with the highest velocities and with the smallest angle of incidence (Doppler angle). That means that at the outlet of a stenosis with diverging streamlines the best Doppler angle may not be parallel to the vessel axis (Fig. 1). Helical flow organisation and disturbances due to tortuosity are further factors making a correct angle estimation difficult or impossible even using color flow as a guide. The possible error converting Doppler shift to velocity increases with increasing Doppler angle due to the cosine function (Doppler equation). Therefore the variability of velocity estimations is higher compared to simple frequency recordings. Beside disturbed flow technical factors have to be considered. Intrinsic spectral broadening is due to beam spreading [7]. For recording Doppler signals with a linear probe a series of transducer elements are pulsed to generate and direct the wave-front. As a consequence the recorded

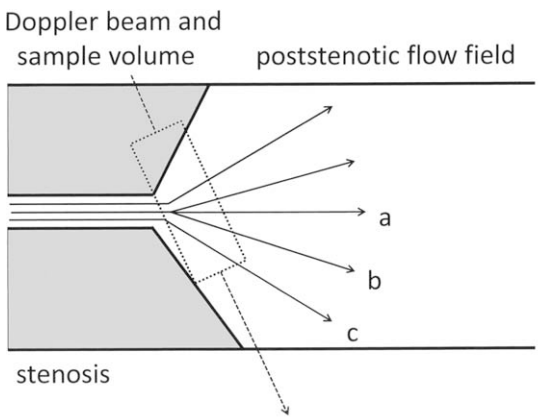

Figure 1 Possible error calculating velocity in disturbed flow. Schematic poststenotic flow field with diverging flow lines. The sample volume (dotted lines) is set immediately at the outlet of a stenosis. Each flow line represents the same velocity. The highest Doppler frequency (envelope of the spectral waveform) will be recorded from the flow line (c) due to the small angle of incidence. Overestimation of peak velocity (PSV) results if it is calculated using the angle of insonation (a) or (b). In practice the sample volume often covers the canal and the outlet of a stenosis.

spectrum is composed of signals originating from different angles of insonation creating spectral broadening [12]. All this may lead to considerable overestimation of velocities in the stenosis. This ''error'' is highly variable depending on the individual circumstances (flow and insonation). On the other hand underestimation of PSV can result from insufficient gain or a low wall filter. In this case the sample volume contains few fast moving blood cells (jet) and many slow ones (eddies) the signal amplitude of the fast ones may be too small in relation to the slow ones being displayed [6].

Hemodynamic influences

Velocity in a stenosis (PSV) depends not only on area restriction but also on the resulting pressure drop. This pressure drop is smaller in case of good collateral supply to the irrigated territory [14]. This results in a reduced flow volume and flow velocity in the severely stenosed artery. On the contrary very high velocities can be recorded from the same degree of stenosis when there is no collateral supply available. A contralateral occlusion leads also to increased velocities in a stenosis [5] but only in case of functioning cross flow. The highest velocities will be seen in 80—90% stenoses. In near occlusion, velocities are lower and variable [1,14,15]. Therefore the PSV alone cannot differentiate between a moderately stenosed artery and a nearly occluded one.

Grading carotid stenosis by means of Doppler duplex sonography needs a multiparametric approach

PSV for grading a stenosis has only a limited value. Therefore additional criteria are mandatory. The method is combining these criteria in grading carotid stenosis in well defined categories: the first question to ask is whether a stenosis has any hemodynamic effect. This happens in a stenosis of ≥70 NASCET [14]. The most important sign is reversal of flow in the ophthalmic artery and in the ipsilateral anterior cerebral artery signifying collateral flow (criterion 4, Table 1). This does not differentiate a stenosis from occlusion of the ICA, but in case of stenosis this indicates undoubtedly a severe and hemodynamically relevant one. PSV is high (criterion 2) except in near occlusion or in the rare condition of additional severe intracranial stenosis. Among the severe, ≥70% stenoses criterion 3 (poststenotic flow velocity, beyond flow disturbances) allows a further differentiation because with increasing narrowing flow volume and velocity are decreasing [14]. This is not found in a stenosis below 70% [14]. The guidelines [1,10] differentiate within the group of high degree stenoses (≥80%) those with a poststenotic velocity drop to ≤30 cm/s as very high (90%). A side to side comparison of the waveform and velocities of the distal ICA is helpful to make clear not only the reduction of PSV but also a reduced poststenotic pulsatility on the side of the stenosis. In case there is no sign of hemodynamic compromise, a stenosis may be moderate (50—60%) or of lower degree. With a moderate stenosis there is still a considerable local increase of velocities, whereas this is not the case in low degree stenosis. This last category is best demonstrated by B-Mode ultrasound with the unique advantage to demonstrate wall thickening with high spatial resolution. The width of the stenotic canal can often be measured in higher degrees of stenosis as well with B-mode imaging. The diameter can then be related to the distal one for measuring the degree of stenosis following the NASCET method, but this is only possible with excellent conditions for insonation. Color Doppler is helpful in delineating plaques of low echogenicity or proving absence of flow in the occluded ICA. But it does not allow precise diameter measurements due to its low frame rate and a huge influence of the gain. Grading of stenoses above 50% is the basis of clinical decisions. Combining morphologic and several hemodynamic features allows a reliable description of at least four classes of stenosis. Such a multiparametric approach avoids severe misclassification as is done with a simplified PSV criterion or its derivates alone (end diastolic velocities in the stenosis, ratio of velocities ICA/CCA). Secondary criteria may be helpful in supporting the diagnosis as the extend of flow disturbances being most pronounced in a 70—80% stenosis and diminishing together with a reduced flow volume in very a high degree stenosis

Is it justified to use ultrasonography as the only method to decide about interventions on the internal carotid artery?

In a high degree stenosis the hemodynamic effect is shown by the appearance of collateral flow, which is driven by the poststenotic pressure drop. Another effect is a poststenotic decrease of velocity and pulsatility of flow. All these effects can be measured reliably by extra- and intracranial Doppler duplex sonography. The question is whether the trial result that surgery is highly beneficial in case of a symptomatic ≥70% NASCET stenosis as measured by angiography can be translated into: beneficial in case of a ''hemodynamically relevant stenosis'' because 70% stenosis

is the threshold from which a pressure drop and decreased poststenotic flow can be observed. This seems reasonable but is so far not accepted as level one evidence. [8]. A meta-analysis of studies correlating PSV and percent of stenosis as measured by angiography showing a considerable disagreement was the background of not accepting ultrasonography. The old concept of a multiparametric diagnosis was not considered. However it has been used and taught over decades. New technical elements have been continuously introduced. But there is a lack of well designed and large studies for this concept, including all these new techniques. In older publications e.g. the definition for measuring the degree of stenosis (NASCET or ECST) is missing. This is one of the reasons why, they do not add very much to the evidence. Even with such new studies some disagreement between methods will persist as explained above. Clinically most useful would be to repeat randomized carotid surgery trials with ultrasonography as criterion for decision in symptomatic patients. However it is ethically not justified to randomize for this question again. With an asymptomatic carotid stenosis the decision about invasive measures is more delicate and controversial as the risks of angiography is small but real. Nevertheless recent recommendations of the AHA accepted duplex sonography for indicating invasive treatment of asymptomatic patients [3]. This makes evident the dependence of consensus recommendations on the time and design of selected studies.

How to proceed in practice?

Training, quality control and certification are prerequisites before using Doppler duplex sonography for decision making. Documentation has to be comprehensive and conclusive. These prerequisites are the same as for other methods. Vascular ultrasonography is non-invasive but not ''quick and easy''.

In case of definitely low or high degree disease as shown by using several main criteria, decisions may be based directly on the sonographic diagnosis. Then angiography is not justified (risk and expenses) just for additional documentation. In case of a symptomatic patient with a diagnosis in between both of these situations the decision may be based on additional imaging with angiography (intraarterial, CTA, MRA) in case of unfavourable insonation conditions or contradictory findings.

The presently available guidelines shall provide a common terminology and promote the diagnosis based on a set of weighted criteria.

Acknowledgement

The author thanks Alfred Persson M.D. (Wellesley Massachusetts) for kindly reviewing the text.

References

[1] Arning C, Widder B, von Reutern GM, Stiegler H, Gortler M. Revision of DEGUM ultrasound criteria for grading internal carotid artery stenoses and transfer to NASCET measurement. Ultraschall Med 2010;31:251—7.

[2] Eliasziw M, Rankin RN, Fox AJ, Haynes RB, Barnett HJM, North American Symptomatic Carotid Endarterectomy Trial (NASCET) Group. Accuracy and prognostic consequences of ultrasonography in identifying severe carotid artery stenosis. Stroke 1995;26:1747—52.

[3] Goldstein LB, Bushnell CD, Adams RJ, Appel LJ, Braun LT, Chaturvedi S, et al. Guidelines for the primary prevention of stroke: a guideline for healthcare professionals from the American Heart Association/American Stroke Association. Stroke 2011;42:517—84.

[4] Grant EG, Benson CB, Moneta GL, Alexandrov AV, Baker JD, Bluth EI, et al. Carotid artery stenosis: gray-scale and Doppler US diagnosis—Society of Radiologists in Ultrasound Consensus Conference. Radiology 2003;229:340—6.

[5] Henderson RD, Steinman DA, Eliasziw M, Barnett HJ. Effect of contralateral carotid artery stenosis on carotid ultrasound velocity measurements. Stroke 2000;31:2636—40.

[6] Kaps M, von Reutern GM, Stolz E, von Büdingen HJ. Ultraschall in der Neurologie, 2 Auflage. Stuttgart, New York: Thieme; 2005.

[7] Kremkau FW. Diagnostic ultrasound, principles and instruments. 5th ed. Philadelphia: W.B. Saunders Company; 1998.

[8] Latchaw RE, Alberts MJ, Lev MH, Connors JJ, Harbaugh RE, Higashida RT, et al. Recommendations for imaging of acute ischemic stroke: a scientific statement from the American Heart Association. Stroke 2009;40:3646—78.

[9] North American Symptomatic Carotid Endarterectomy Trial (NASCET) Collaborators. Beneficial effect of carotid endarterectomy in symptomatic patients with high-grade carotid stenosis. N Engl J Med 1991;325:445—53.

[10] von Reutern GM, Goertler MW, Bornstein NM, Del Sette M, Evans DH, Hetzel A, et al. Recommendations for grading carotid stenosis by means of ultrasonic methods. Stroke 2012;43:916—21.

[11] Rothwell PM, Gibson RJ, Slattery J, Sellar RJ, Warlow CP. Equivalence of measurements of carotid stenosis. A comparison of three methods on 1001 angiograms. European Carotid Surgery Trialists' Collaborative Group. Stroke 1994;25: 2435—9.

[12] Thrush JA, Evans DH. Intrinsic spectral broadening: a potential cause of misdiagnosis of carotid artery disease. J Vascular Invest 1995;1:187—92.

[13] Spencer MP, Reid JM. Quantification of carotid stenosis with continuous-wave (C-W) Doppler ultrasound. Stroke 1979;10:326—30.

[14] Spencer MP. Hemodynamics of arterial stenosis. In: Spencer MP, editor. Ultrasonic diagnosis of cerebrovascular disease. Dordrechts: Martinus Nijhoff Publishers; 1987.

[15] Widder B, von Reutern GM, Neuerburg-Heusler D. Morphologic and Doppler sonographic criteria for determining the degree of stenosis of the internal carotid artery. Ultraschall Med 1986;7:70—5.